

# **Intraoral schwannoma (neurilemmoma): An unusual anterior palatal swelling - A Case report**

**Neelampari R Parikh\* Nimisha Desai\*\***

\*M.D.S, Professor and Head, Department of oral & maxillofacial pathology, \*\*M.D.S, Professor & Head, Karnavati School of Dentistry, Gandhinagar, India.  
Contact: neeparikh@yahoo.com

## **Abstract**

Schwannoma (Neurilemmoma) is a benign nerve sheath tumor that is composed entirely of well differentiated Schwann cells. Intraosseous neurilemmomas are rare and they represent less than 1% of all benign primary bone tumors. It is important to highlight that the Schwannoma is usually found in the head and neck, and rarely in the oral cavity. Schwannoma is a benign tumor that originates from the Schwann cells of the peripheral nerves. They are usually asymptomatic, do not recur, and malignant transformation is rare. We report here on an additional case of intraosseous neurilemmoma that was located in unusual location i.e. anterior palatal region.

**Key words:** Schwannoma (neurilemmoma), anterior hard palate, oral cavity.

## **Introduction:**

Neurilemmoma was first described by Verocay in 1910. He called it "Neurinoma" then. In 1935, the term 'Neurilemmoma' was coined by Stout.<sup>1,2</sup> Intraoral schwannomas are uncommon and intraosseous ones are even rarer. The intrabony lesions account for less than 1% of the central neoplasms.<sup>3,4</sup> It is also named neurilemoma, neurinoma and Schwann cell tumor.<sup>5</sup> Schwannoma has been defined as a benign, encapsulated neoplasm that arises in the

*P- ISSN*  
*0976 – 7428*

*E- ISSN*  
*0976 – 1799*

*Journal of  
International  
Oral Health*

*Oral & Maxillofacial  
Pathology*

*Case Report*

*Received: Oct, 2010*  
*Accepted: Nov, 2010*

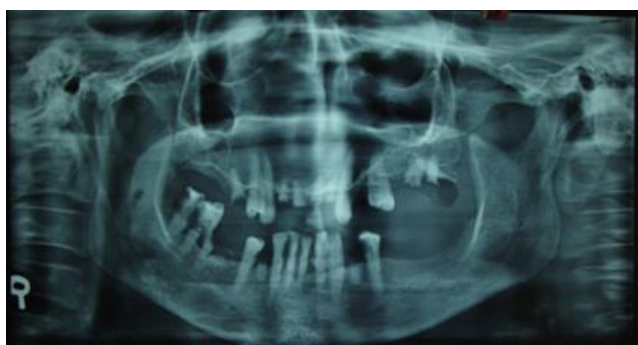## **Bibliographic listing:**

*EBSCO Publishing  
Database, Index  
Copernicus, Genamics  
Journalseek Database*

nerve fiber. This neoplasm is composed primarily of Schwann cells in a poorly collagenized stroma.<sup>6</sup> The schwannoma is usually a solitary lesion, and can be multiple when associated with neurofibromatosis.<sup>6</sup> This article reports the case of an intraosseous schwannoma unusually located in anterior hard palate of 64 years old female patient.

### Case report:

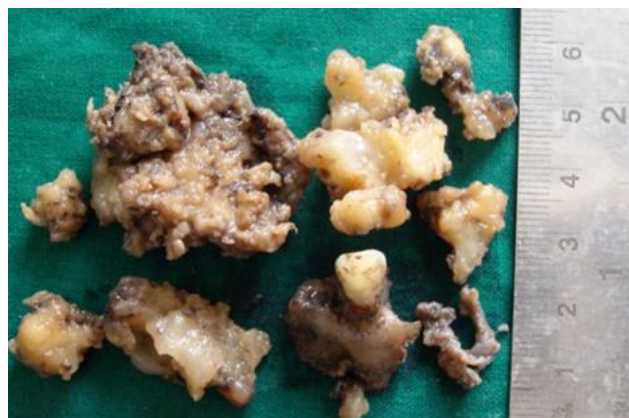A 64 year old female patient reported to the Karnavati school of Dentistry, Gandhinagar with a chief complaint of a swelling on the palate, present for three years. History revealed that the swelling had gradually increased in size since its onset. The swelling was not associated with pain, discharge or paraesthesia. The mass was firm and mucosa over the mass was normal without erythematous or ulcerative changes. No remarkable medical history revealed except for hypertension. Clinical examination revealed roughly oval swelling; measuring 2cm×2cm, and the surface appeared smooth in anterior hard palate region. Orthopantograph showed a well-defined radiolucency with a sclerotic lining in anterior hard palate in relation to maxillary anterior teeth.(Figure:1) Thus, a provisional diagnosis after clinical and radiographic examination was of palatal cyst made.



**Figure: 1** Orthopantograph showing radiolucent area in relation with maxillary anterior teeth.

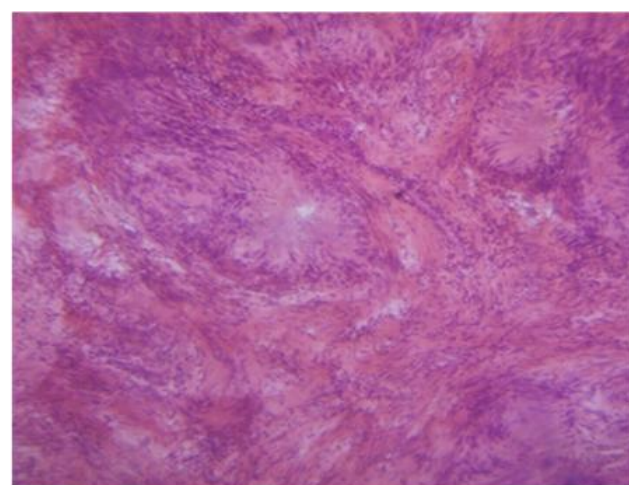
All laboratory investigations carried out and found to be within normal limits before the surgical procedure. Surgical removal of the lesion was done under local anesthesia without

complication. Tissue samples were submitted in one large mass and few small pieces for histopathological examination. (Figure: 2)



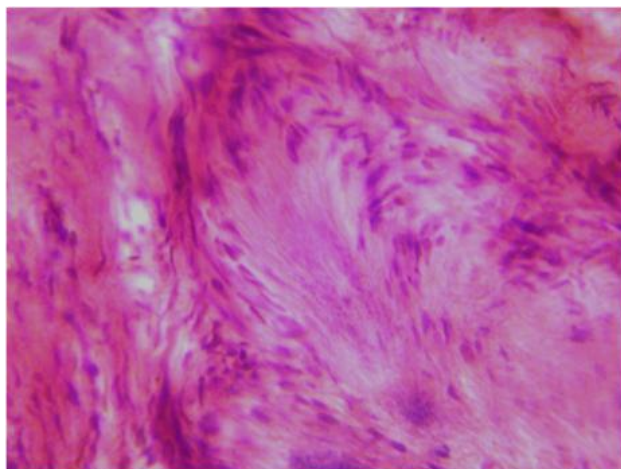
**Figure: 2** Photograph of Gross specimen

Grossly, the large specimen consisted of a mass of grayish white tissue. The surface was rough and had a gritty texture when cut. Small pieces were yellowish and had smooth shiny surface. The tissues were then processed, and multiple sections were stained with hematoxylin and eosin. Hematoxylin & Eosin stained sections showed presence of encapsulated lesion composed of bundles of spindle cells arranged in two types of cellular pattern: Antoni type A and type B. The Antoni type A tissue characterized by Schwann cells that are closely

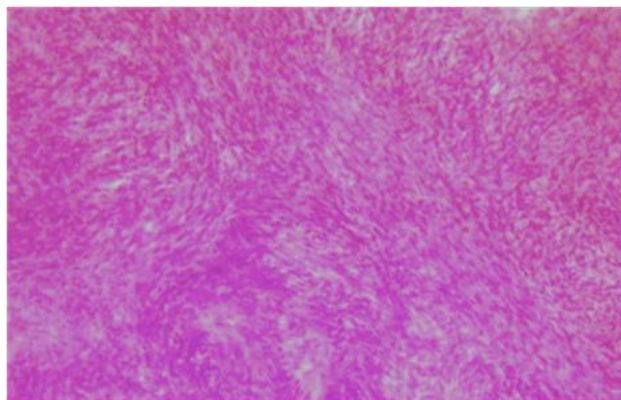


**Figure: 3** Photomicrograph showing Antoni type A tissue with varocay bodies. (H & E Stain. 10x)

packed, forming bundles or arranged in rows with elongated, palisaded nuclei around an acellular eosinophilic area. ( Figure: 3) Free bands of amorphous substance between the rows of nuclei constitute the so-called Verocay bodies. ( Figure: 4) In the Antoni B tissue revealed less number of cells and less organization, where the fusiform cells are widely separated, dispersed in a loose and random fashion ( Figure: 5)



**Figure:4** Photomicrograph showing varocay body with palisaded arrangement of nuclei. (H & E Stain 45x)



**Figure: 5** Photomicrograph showing Antoni type B tissue. (H & E Stain. 10x)

In addition, areas of necrosis, hyalinization and myxoid degeneration also noticed. From histopathologic features confirmed diagnosis of intraosseous schwannoma was given.

## Discussion:

The schwannoma is a rare benign neural tumor, arising from the neural sheath Schwann cells of the peripheral, cranial, or autonomic nerves.<sup>7</sup> It does not arise from cranial nerves I and II (optic and olfactory nerves), because they lack Schwann cells.<sup>8</sup>

Two types are distinguished : central or peripheral schwannoma, located in bone or in soft tissues respectively.<sup>5</sup>

The etiology of the schwannoma is unknown. It is believed to originate from a proliferation of Schwann cells in the perineurium causing displacement and compression of the adjacent nerve.<sup>5</sup>

Chi et al.<sup>3</sup> has reported that schwannoma of the jaw occurred in the age range of 8-72 years, with the average age of 64 years, and there is a definite female predilection. These features coincide with the case presented in our study. The patient of the present case was a female aged 64 years. Amongst the jaws, the mandible is a favored site compared to the maxilla. Mandibular schwannomas are mostly localized to the posterior body and the ascending ramus and can also involve the symphysis region.<sup>3</sup> The location in the palate, as in the case presented, is quite rare.

The tumor is solitary, with a smooth surface, and slow asymptomatic growth; although the clinical symptomatology depends on the nerve of origin.<sup>8</sup> The clinical presentation of this case was a solitary painless, smooth surfaced swelling.

Radiographically, schwannomas of either jaw are well-demarcated, unilocular radiolucencies with a thin sclerotic border. Additional features such as external root resorption, cortical thinning, cortical expansion, and peripheral scalloping can be evident.<sup>3</sup> As diagnostic tools, ultrasonography, computed tomography and magnetic resonance imaging may be helpful for estimation of tumor margins as well as infiltration of surrounding structures.<sup>9</sup>

In the present case, the preoperative diagnosis is quite difficult, among other reasons because this

is an infrequent tumor and is not usually suspected in the oral cavity as well as less common intraosseous location in the anterior region of the palate. The histopathologic examination provided a definitive diagnosis for the case. Clinically, two forms of oral schwannoma can occur: the most frequent is the encapsulated in which the tumor is surrounded by dense fibrous connective tissue; the other is pediculate, resembling a fibroma.<sup>10</sup>

The microscopic aspect was characteristic and easily distinguishable from other lesions. There are two types of tissue arrangement: Antoni-A and Antoni-B. Alternation between Antoni A and B regions is common. Antoni-A type is composed of aligned fusiform cells, forming a typical palisade. Between the fibrils there are small eosinophilic masses called Verocay bodies. Antoni-B type is composed of a smaller number of cells and the spindle cells are randomly arranged within a loose myxomatous stroma.<sup>11</sup> In this case, both tissues were predominantly revealed.

Immunohistochemical examination could assist in lesion differentiation. Chrysomali et al.<sup>2</sup> observed an intense positive reaction to S100 in schwannoma and palisaded encapsulated neuroma. Intensive reaction to CD57 is observed in traumatic neuroma, while capsular epithelial membrane antigen (EMA) and CD34 stainings are observed in schwannoma. According to Chrysomali et al. the tumoral cells with Antoni A show greater intensity scores compared to Antoni B tumor pattern.

The treatment of choice is excision. The encapsulated form is enucleated easily, whereas the nonencapsulated requires normal tissue margins to avoid relapse. If the nerve of origin is visualized, an attempt should be made to separate carefully to preserve function, although this is sometimes not possible.<sup>5, 10</sup> In our case the connection with the nerve could not be seen. The prognosis is very good since it does not usually recur. Fortunately, malignant transformation of neurilemmoma is exceedingly

rare, and no such transformation has been reported for intraosseous neurilemmoma.<sup>12</sup>

### Conclusion:

An important conclusion that has evolved from this case series is that the differential diagnosis of painless nodules in head and neck must include schwannomas. It is likely that nerve sheath neoplasms are more common than previously reported. Prognosis is excellent as the tumor is benign, and recurrence is nearly unknown, so it is possible and indeed recommended to preserve nerve integrity with careful dissection.

### References:

- 1) Baranovi M, Macan D, Begovi EA, Luksic I, Brajdi D, Manojlovi S. Schwannoma with Secondary erosion of mandible: Case report with review of literature. *Dentomaxillofac Radiol* 2006; 35:456-460.
- 2) Chrysomali E, Papanicolaou SI, Dekker NP, Regezi JA. Benign Neural tumors of the oral cavity. *Oral Surg Oral Med Oral Pathol Oral Radiol Endod* 1997; 84:381-390.
- 3) Chi AC, Carey J, Muller S. Intraosseous schwannoma of the mandible: a case report and review of the literature. *Oral Surg Oral Med Oral Pathol Oral Radiol Endod* 2003; 96: 54-65.
- 4) Kowatsch E, Feichtinger M, Zemann W, Karpf E, Karcher H. Extraosseous Schwannoma of the mental nerve clinically simulating intraosseous. *J Oral Pathol Med* 2006; 35:517-519.
- 5) Artzi Z, Taicher S, Nass D. Neurilemmoma of the mental nerve. *J Oral Maxillofac Surg*. 1991; 49:196-200.
- 6) Wright BA, Jackson D. Neural tumors of the oral cavity. A review of the spectrum of benign and malignant oral tumors of the

cavity and jaws. *Oral Surg Oral Med Oral Pathol* 1980;49: 509-522.

- 7) Hatziotis JC, Asprides H. Neurilemmoma (schwannoma) of the oral cavity. *Oral Surg* 1967;24:510-526.
- 8) Yang SW, Lin CY. Schwannoma of the upper lip: case report and literature review. *Am J Otolaryngol.* 2003; 24:351-354.
- 9) Asaumi J, Konouchi H, Kishi K. Schwannoma of the upper lip: ultrasound, CT and MRI findings. *J Oral Maxillofac Surg* 2000; 58:1173-1175.
- 10) Hribernik SJ, Gould AR, Alpert B, Jones JL. Well-circumscribed mass of the lateral floor of the mouth. *J Oral Maxillofac Surg.* 1992; 50:741-746.
- 11) Neville BW, Damm DD, Allen CM, Bouquot JE. *Oral & Maxillofacial Pathology*, 3<sup>rd</sup> Ed. Philadelphia: WB Saunders Company, 2009. Chapter:12. Soft tissue tumors: 526-528
- 12) Agha FP, Lilienfeld RM. Roentgen features of osseous neurilemmoma. *Radiology* 1972; 102: 325-326.

Source of Support: Nil

Conflict of Interest: Not Declared

